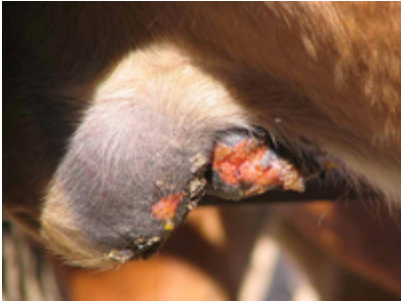

Images of Vesicular Stomatitis in Horses in Wyoming

2005 Outbreak




Edematous sheaths with ulceration (image at left) of tip of penis. Horse

Images: Danny Cosner, AHT
USDA-APHIS-VS-WY



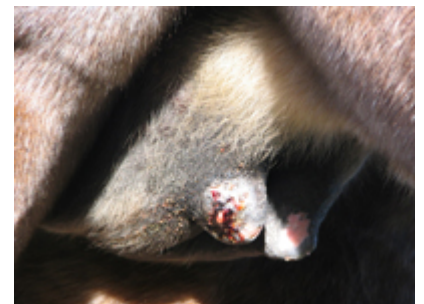Coronitis (swelling of coronary band) in horse recovering from VSV. Green coloration of the distal limb is due to medication.

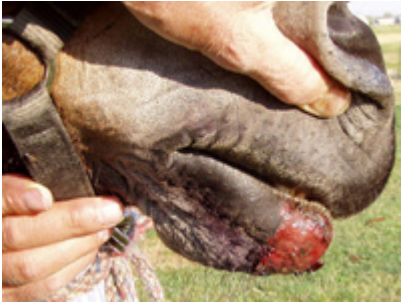Images: Danny Cosner, AHT
USDA-APHIS-VS-WY



Ulcerated teat. Horse

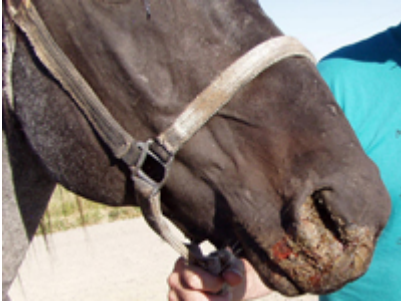
Images: Danny Cosner, AHT
USDA-APHIS-VS-WY






**Ulceration of skin of
rostral mandible. Horse**

Image: Dr. Bill Wilson, Riverton, WY



**Ulceration of skin of
muzzle and nares. Horse**

Images: Dr. Bill Wilson, Riverton, WY



Click [HERE](#) for link to Wyoming Livestock Board's web page. It has maintained a running tally of VSV in Wyoming by county, date and species

*Donal O'Toole
Wyoming State Veterinary Laboratory*